

See discussions, stats, and author profiles for this publication at: <https://www.researchgate.net/publication/260128093>

# A Chronic Toxicity Study of the Ground Root Bark of *Capparis erythrocarpus* (Cappareceae) in Male Sprague–dawley Rats

Article in *Pakistan Journal of Biological Sciences* · December 2013

DOI: 10.3923/pjbs.2013.1706.1713 · Source: PubMed

CITATIONS

5

READS

105

4 authors, including:



**Orleans Martey**  
University of Otago

28 PUBLICATIONS 95 CITATIONS

[SEE PROFILE](#)



**Archibald A. Sittie**

26 PUBLICATIONS 508 CITATIONS

[SEE PROFILE](#)



**Laud Kenneth Okine**  
University of Ghana

68 PUBLICATIONS 465 CITATIONS

[SEE PROFILE](#)

Some of the authors of this publication are also working on these related projects:



DANIDA [View project](#)



CPMR Reasearch [View project](#)

## A Chronic Toxicity Study of the Ground Root Bark of *Capparis erythrocarpus* (Cappareceae) in Male Sprague-dawley Rats

<sup>2</sup>O.N.K. Martey, <sup>3</sup>G.E. Armah, <sup>2</sup>A.A. Sittie and <sup>1</sup>L.K.N. Okine

<sup>1</sup>Department of Biochemistry, Cell and Molecular Biology, University of Ghana, Legon, Accra, Ghana

<sup>2</sup>Centre for Scientific Research into Plant Medicine, P.O. Box 73, Mampong-Akuapem, Ghana

<sup>3</sup>Electron Microscopy and Histopathology Unit, Noguchi Memorial Institute for Medical Research, College of Health Sciences, University of Ghana, Legon, Accra, Ghana

**Abstract:** The safety evaluation of *Capparis erythrocarpus* (CE) on chronic administration at 18 and 180 mg kg<sup>-1</sup> body weight for 6 months was investigated in male Sprague-Dawley rats. The effects of CE on certain serum biochemical, haematological, urine and histopathological determinations were used as indices of organ specific toxicity. Also the effects of CE on rat blood clotting time and pentobarbital-induced sleeping time were determined. Results indicate that CE had no effect on urine, haematological and serum biochemical indices at termination of treatment with the exception of serum ALT level which was significantly ( $p < 0.05$ ) attenuated in a dose-dependent fashion (21-35%). There were also no differences in blood clotting time and pentobarbital-induced sleeping time between CE-treated and control animals. Histopathological studies showed that CE did not adversely affect the morphology of the liver, kidney and heart tissues. However, lungs of CE-treated animals showed slight but insignificant inflammatory response in alveolar areas and Clara cell hyperplasia without the thickening of alveolar septa and bronchiolar epithelial wall. Organ weights were not adversely affected by CE treatment. There were significant ( $p < 0.05$ ) changes in weight of CE-treated animals with duration of treatment compared to control. These results suggest that there is no organ specific toxicity associated with chronic administration of CE in rats and its ability to reduce body weight may be useful for slimming in obese persons.

**Key words:** *Capparis erythrocarpus*, toxicity, histopathology, rat, organs

### INTRODUCTION

Sirapac powder is a milled root bark of *Capparis erythrocarpus* (CE) which belongs to the family Cappareceae, previously known as Cdapparidaceae. The *Capparis* genus comprises some 650 sp., of small trees and shrubs in 30 genera which are found principally in tropical and warm temperate regions. However, few species may be cultivated (Hutchinson, 1967).

Members of this family contain thioglucosides also known as glucosinolates which release isothiocyanates (mustard oil) when the plant is damaged. The plants yield methyl isothiocyanate from methyl glucosinolate otherwise known as glucocapparin. This mustard oil has skin irritant property and may also have contact allergenic property (Mitchell and Jordan, 1974; Richter, 1980).

The seeds and the juice of pounded leaves of CE are used against child convulsive fever and the pounded root is used in severe abscess whilst vapour from the pounded root is used for the treatment of inflammation of the

connective tissue of the eye in Tanzania and India (Hedberg *et al.*, 1982). However, powdered root of CE has been processed and used for the management of arthritis over 25 years at the Center for Scientific Research in to Plant Medicine (CSRPM), Mampong, Akuapem, Ghana.

Despite its long period of usage in the management of arthritis, its safety in chronic use has not been pre-clinically evaluated. The aim of this study is to scientifically evaluate the safety of powdered CE in male Sprague-Dawley rats on chronic administration to validate its clinical use.

### MATERIALS AND METHODS

**Reagents and chemicals:** Test kits; aspartate aminotransferase (AST), alanine aminotransferase (ALT), gamma-glutamyl-transferase ( $\gamma$ -GT), bilirubin (Direct and Total), Albumin, Creatinine, Urea, Creatinine-kinase (CK-MB) were purchased from Cypress Diagnostics (Belgium). Urine test strips (UroColor™ 10) were supplied

by Standard Diagnostics Inc., Korea and pentobarbital was obtained from Sigma Chemical Co. (St. Louis, Mo, USA). All other chemicals were purchased in the purest form available from British Drug Houses (BDH) Ltd., (Poole, UK).

**Animals:** Male Sprague-Dawley rats (150-200 g) were obtained from the Animal Unit of Centre for Scientific Research into Plant Medicine, Mampong-Akuapem, in the Eastern Region of Ghana. The animals were fed on powered feed obtained from Ghana Agro Food Company (GAFCO) Tema, Ghana. The research was conducted in accordance with the internationally accepted principles for laboratory animal use and care as found in the US guidelines (NIH Publication No. 85-23, revised in 1985).

**Sirrapac powder preparation:** Air dried root bark (20 kg) of CE was oven-dried at 65°C for 10 h. This was milled into fine powder and re-heated at 37°C for 3 h after which it was bagged at room temperature under aseptic conditions.

**Treatment of animals:** Three groups of six male rats were kept in 18 separate metabolic cages. Group 1 was kept as a control and received normal chow *ad libitum* for 6 months. Groups 2 and 3 were treated with 18.0 mg kg<sup>-1</sup> b.wt. day<sup>-1</sup> (normal human dose) and 180.0 mg kg<sup>-1</sup> b.wt. day<sup>-1</sup> (10x the normal dose) of CE powder, respectively mixed with their feed for 6 months. All animals received sterilized distilled water *ad libitum*. The animals in the metabolic cages of each group were weighed on day zero (baseline) and fortnightly thereafter.

**Blood Sampling and blood clotting time:** Blood samples of rats in each treatment group were obtained by tail bleeding at baseline and at 3 and 6 months into Eppendorf tubes and blood clotting time determined and then placed on ice. These were centrifuged at 4000xg for 5 min (Denley BS 400, England) and the supernatant (serum) obtained, stored at -40°C for biochemical analysis. Another set of blood samples were collected into tubes already coated with tri-sodium citrate (Westergreen ESR, UK) for haematological analysis within 24 h.

**Serum biochemical and haematological analyses:** Serum ALT, AST, GGT, total bilirubin, direct bilirubin, albumin, CK-MB, creatinine and urea of control and CE-treated rats were determined using protocols from cypress diagnostic kits (Belgium) with a semi-autoanalyzer (Photometer 4040; Robert Riele G and Cole-2000, Germany). In haematological analysis, Red Blood Cells (RBC), White Blood Cells (WBC), haematocrit (HCT), haemoglobin (Hb) and platelet (PLT), Mean Cell Volume

(MCV), Mean Platelet Volume (MPV) and thrombocytes (PCT) of control and CE-treated rats were determined with Haema-screen 10 (Hospitex Diagnostics, Italy) in accordance with standard protocol. The system is computerized to automatically determine and display the haematological data for each blood sample.

**Urinalysis:** Urine samples of control and CE-treated rats, produced as a result of involuntary discharges, were collected on clean ceramic tiles at baseline and after 3 and 6 months of treatment. Urine glucose, bilirubin, ketones, specific gravity, pH, proteins urobilinogen, nitrate, blood and leukocytes were determined using urine reagent strips (UroColor™ 10, Standard Diagnostic Inc., Korea).

**Histology:** At the end of the six month treatment period (termination), two rats from the control and CE-treated groups were euthanized by cervical dislocation and the heart, lungs, liver, kidney and spleen were excised and weighed. These organs, with the exception of the spleen, were then fixed in 10% formaldehyde and dehydrated with increasing concentration of ethanol (85-100%). The tissues were cleared with chloroform and impregnated with paraffin wax. Sections were cut, stained with haematoxylin and eosin and mounted on slides for light microscopic examinations. Tissue sections of the four organs of two other rats at baseline were also prepared (Baker and Silverstone, 1985).

**Pentobarbital-induced sleeping time:** *In vivo* drug interaction was assessed by the pentobarbital-induced sleeping time. Control and CE-treated animals were each given intraperitoneal injections of pentobarbital. All animals were placed on their backs after they had lost consciousness and the time between the animals falling asleep and regaining consciousness was recorded (Nyarko *et al.*, 1999).

**Statistical analysis:** One-way analysis of variance (ANOVA) and independent sample t-test was conducted between control and tests to determine statistical significance. The 5% level of probability was used as criterion of significance in all instances. All statistical tests were performed with spss statistical software version 10.0.

## RESULTS

**Body and organ weights:** The percentage change in mean body weight with period of treatment and organ wet weights at termination of treatment in control and CE-treated animals are shown in Fig. 1 and Table 1,

Table 1: Mean organs wet weight at termination of treatment with CE

Organ/tissue	Organ weight/body weight (%)		
	Treatment groups <sup>a</sup>		
	Control	CE (18 mg kg <sup>-1</sup> )	CE (180 mg kg <sup>-1</sup> )
Heart	0.27±0.01	0.32±0.02	0.30±0.01
Lungs	0.37±0.02	0.37±0.03	0.59±0.14
Liver	2.56±0.14	2.17±0.06	2.35±0.22
Kidney	0.51±0.01	0.45±0.01	0.62±0.08
Spleen	0.16±0.01	0.17±0.02	0.16±0.02

Results are Means±SEM for N = 6, <sup>a</sup>For treatment regimen

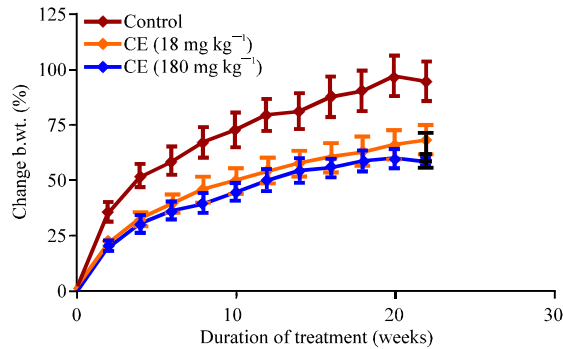


Fig. 1: Percentage changes in body weight of control and CE-treated Sprague-Dawley rats with duration of treatment. Each point represents Mean±SEM (N = 6). <sup>a</sup>Value significantly different from control, p<0.05. For details of treatment regimen

respectively. The results showed a significant reduction (p<0.05) in the change in body weight of CE-treated animals compared to control, although there was no significant difference (p>0.05) in body weight changes between CE-treated animals with time. The animals on CE appeared leaner than the controls although the length of their hind legs and femur as well as food intake of all treatment groups were similar (results not shown). There were insignificant changes (p>0.05) in the organ weights, expressed as percentage of body weight, at termination between control and CE-treated animals.

**Serum biochemistry and urinalysis:** The effects of chronic administration of CE to rats on selected serum biochemical and urine parameters at termination of treatment are shown in Table 2 and 3. The serum biochemical indices indicate that CE caused significant dose-dependent reductions (p<0.05) in the levels of ALT at the 18 mg kg<sup>-1</sup> (21%) and 180 mg kg<sup>-1</sup> (35%) dose levels. However, there were insignificant (p>0.05) changes in serum GGT, AST, total and direct bilirubin, albumin, urea, creatinine and CK-MB in the CE-treated animals when compared to controls. Dipstick urinalysis data indicate that there were no significant differences in the levels of urine haemoglobin, blood, bilirubin,

Table 2: Serum biochemical analysis at termination of treatment with CE

Parameter	Treatment group		
	Control	CE (18 mg kg <sup>-1</sup> )	CE (180 mg kg <sup>-1</sup> )
AST (U L <sup>-1</sup> )	59.1±4.100	50.3±4.020	49.8±2.150
ALT (U L <sup>-1</sup> )	29.8±2.070	23.5±1.290*	19.5±1.360*
GGT (IU L <sup>-1</sup> )	2.19±0.19	2.77±0.24	3.94±1.10
Total bilirubin (µmol L <sup>-1</sup> )	1.58±0.19	1.58±0.32	1.03±0.17
Direct bilirubin (µmol L <sup>-1</sup> )	0.55±0.14	0.37±0.12	0.35±0.08
Urea (mmol L <sup>-1</sup> )	4.31±0.42	5.39±0.23	5.42±0.62
Creatinine (µmol L <sup>-1</sup> )	69.4±7.230	58.3±4.860	67.5±18.70
CK-MB (U L <sup>-1</sup> )	548.0±35.00	503.0±520.0	518.0±54.00
Albumin (g L <sup>-1</sup> )	41.4±4.730	37.6±0.680	36.5±1.040

Results are Means±SEM for N = 6, <sup>a</sup>Values significantly different from control, p<0.05, <sup>a</sup>For treatment regimen

Table 3: Effect on indices of urinalysis at termination of treatment with CE

Indice	Treatment group <sup>a</sup>		
	Control	CE (18 mg kg <sup>-1</sup> )	CE (180 mg kg <sup>-1</sup> )
Urobilinogen (mg dL <sup>-1</sup> )	N	N	N
Glucose (mg dL <sup>-1</sup> )	-	-	-
Bilirubin (mg dL <sup>-1</sup> )	-	-	-
Ketones (mg dL <sup>-1</sup> )	±	±	±
Specific gravity	1.01	1.00	1.01
Blood (RBC µL <sup>-1</sup> )	-	-	-
pH	7.7	7.9	7.7
Protein (g L <sup>-1</sup> )	++	+	+
Nitrite	-	±	±
Leukocytes (WBC µL <sup>-1</sup> )	+	+	+

Figures represent means of 6 determinations, -: Absent, N: Normal, ±: Trace and +: Positive, <sup>a</sup>For treatment regimen

Table 4: Effect on hematological indices at termination of treatment with CE

Indice	Treatment group <sup>a</sup>		
	Control	CE (18 mg kg <sup>-1</sup> )	CE (180 mg kg <sup>-1</sup> )
RBC (x10 <sup>6</sup> µL <sup>-1</sup> )	8.24±0.42	8.88±0.16	8.21±0.44
MCV (µ <sup>3</sup> )	64.4±0.87	65.20±1.29	67.3±1.010
HCT (%)	52.9±2.32	58.10±1.72	55.2±3.220
PLT (x10 <sup>3</sup> µL <sup>-1</sup> )	394±56.0	397.00±76.5	321.0±26.30
MPV (µ <sup>3</sup> )	8.83±0.64	8.75±0.64	8.00±0.35
PCT (%)	0.37±0.09	0.37±0.11	0.26±0.02
WBC (x10 <sup>3</sup> µL <sup>-1</sup> )	5.10±0.34	5.36±0.27	4.38±0.53
Hb (g dL <sup>-1</sup> )	12.5±0.42	13.10±0.31	12.8±0.360

Results are Means±SEM for N = 6, <sup>a</sup>For treatment regimen

urobilinogen, proteins, ketones, glucose, nitrite, leucocytes, pH and specific gravity between control and CE-treated animals. The results were similar to baseline values (results not shown).

**Haematological studies:** The effect of CE on certain haematological indices at termination of treatment is shown (Table 4). The results show that there were no significant differences (p>0.05) in all parameters measured between control and CE-treated animals. These results were similar to that at baseline (results not shown).

**Histological studies:** The effects of CE on the histopathology of the liver, kidney, lung and heart tissues at termination of treatment are shown in Fig. 2-5. Results

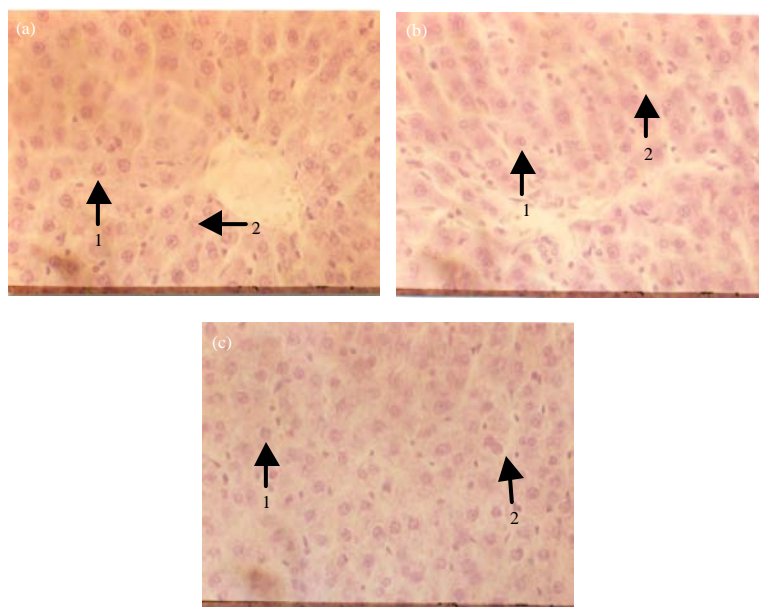


Fig. 2(a-c): Histological appearance of the liver of control (a) Animals at termination showing (1) normal hepatocytes and (2) interstitial spaces and animals treated with normal dose of CE-18 mg kg<sup>-1</sup>, (b) 10x the normal CE dose-180 mg kg<sup>-1</sup> and (c) At termination, showing no differences in appearance of hepatocytes (1) and interstitial spaces (2) compared to control. Morphology of control liver at termination was not different from that at baseline. For details of treatment regimen, Magnification: x132

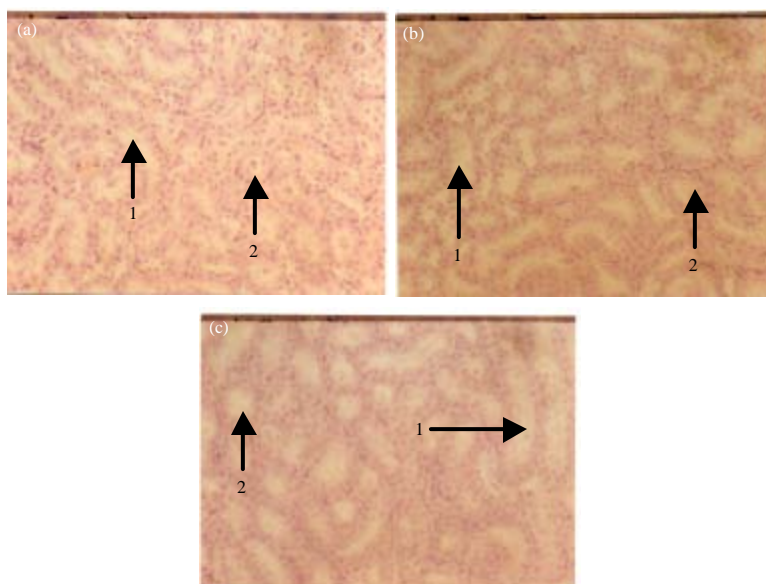


Fig. 3(a-c): Histological appearance of the kidney of control animals at termination (a) Showing (1) normal tubular and (2) glomerular areas and animals treated with normal dose of CE-18 mg kg<sup>-1</sup>, (b) 10x the normal CE dose-180 mg kg<sup>-1</sup> and (c) At termination, showing no differences in tubular (1) and glomerular (2) areas compared to control. Morphology of control kidney at termination was not different from that at baseline. For details of treatment regimen, Magnification: x132

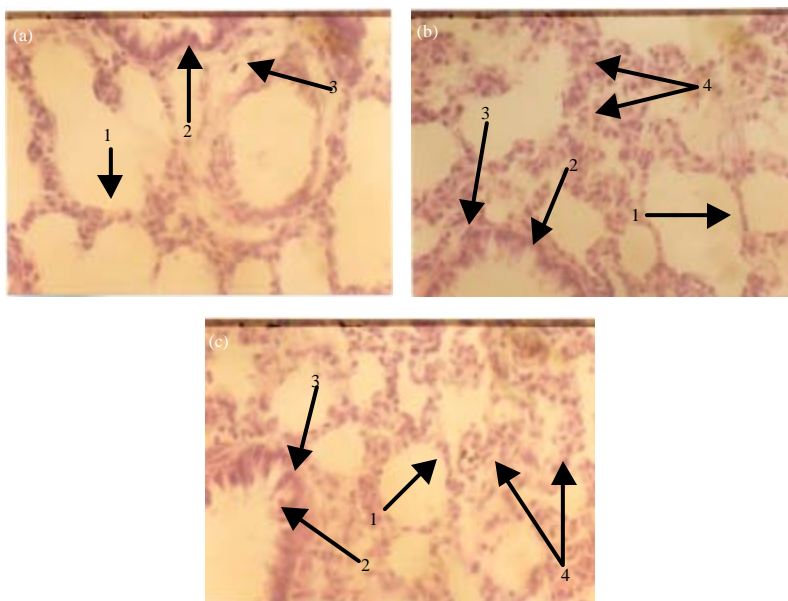


Fig. 4(a-c): Histological appearance of the lung of control animals at termination (a) Showing (1) normal alveolar areas and (2) Clara cells lining a normal bronchiolar epithelial wall and (3) animals treated with normal dose of CE-18 mg kg<sup>-1</sup>, (b) 10x the normal CE dose-180 mg kg<sup>-1</sup> and (c) At termination, showing slight inflammatory response at alveolar areas (4) and slight Clara cell hyperplasia (2) without changes in the bronchiolar epithelial lining (3). Morphology of control lung at termination was not different from that at baseline. For details of treatment regimen, Magnification: x132




Fig. 5(a-c): Histological appearance of the heart of control animals (a) Animals treated with normal dose of CE-18 mg kg<sup>-1</sup>, (b) 10x the normal CE dose-180 mg kg<sup>-1</sup> and (c) At termination, showing no differences in morphology of cardiac tissue. Morphology of control heart tissue at termination was not different from that at baseline. For details of treatment regimen, Magnification: x132

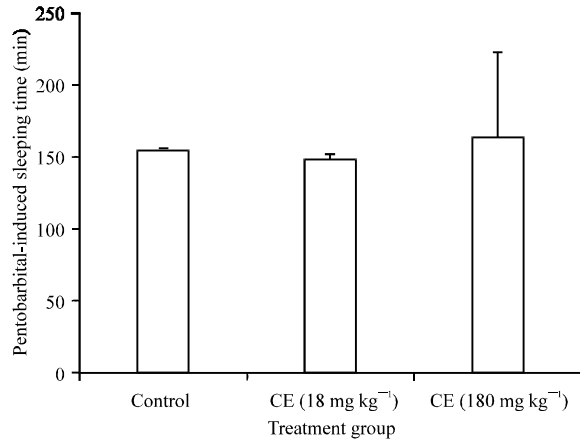


Fig. 6: Effect of pre-treatment of rats with CE on pentobarbital-induced sleeping time. Values are Means±SEM (N = 6), For details of treatment regimen

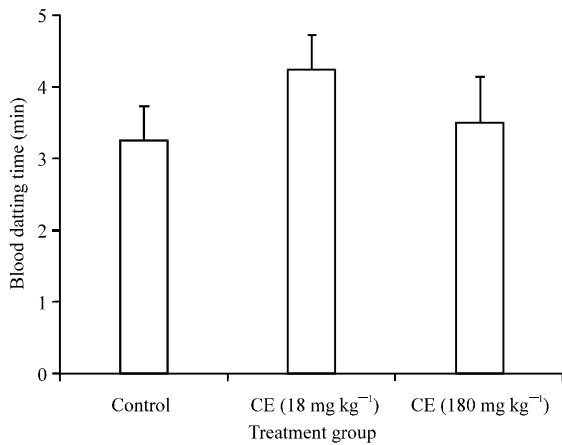


Fig. 7: Effect on blood clotting time at termination of treatment of rats with CE. Results are Means±SEM (N = 6). For details of treatment regimen

showed that CE did not affect the morphology of the liver, kidney and heart tissues (Fig. 2a-c, 3a-c, 5a-c). However, lungs of CE-treated animals showed slight but insignificant inflammatory response in alveolar areas and Clara cell hyperplasia without the thickening of alveolar septa and bronchiolar epithelial wall (Fig. 4a-c).

**Pentobarbital-induced sleeping and blood clotting times:** The effects of pre-treatment with CE on pentobarbital-induced sleeping time and blood clotting time are shown in Fig. 6 and 7. Results indicate that there were no significant differences ( $p > 0.05$ ) in pentobarbital-induced sleeping time and blood clotting time between control and CE-treated animals.

## DISCUSSION AND CONCLUSION

Arthritis is a major debilitating disease that afflicts many in developed and developing countries. The crippling effects of the disease may lead to the loss of many man h to a nation as well as huge costs in medical expenses in view of the fact that some of the most effective anti-inflammatory allopathic drugs are quite expensive. It is, therefore, of importance that new herbal alternatives of equivalent safety and efficacy be developed to meet the needs of sufferers of arthritis in developing countries who are among about 70% of the population who depend on traditional medicine for their primary health care needs.

In this study, we have evaluated the safety of the root bark of *C. erythrocarpus* (CE), used at the CSRPM with ethnomedical evidence for its use in the management of arthritis, in Sprague-Dawley rats. To this end we evaluated the effects of CE on the function and/or morphology of key organs that are essential for the normal function of the body, namely the liver, kidney, lung and heart as well as the bone marrow.

Results from the liver, kidney and cardiac function tests (Table 2) indicates that there was no effect of CE on any of the indices measured when compared to controls with the exception of serum ALT levels which was significantly reduced in a dose-dependent fashion, an indication that CE or its metabolite(s) inhibits ALT activity. It is known that damage to these organs will lead to the release of enzymes (e.g., AST, ALT and ALP) into the blood or the reduction in synthesis (e.g., albumin) or clearance of certain substances (urea and creatinine) from blood leading to the elevation or reduction of their levels in the blood (Gaw *et al.*, 1998). This, therefore, indicates that these organs were not adversely affected by CE treatment. These findings are supported by the histological data which shows that the morphology of these organs was not adversely affected by CE (Fig. 2, 3 and 5). Furthermore, urinalysis data support absence of renal dysfunction or damage.

The lung is the most sensitive organ that can easily be adversely affected by toxic insult by xenobiotics. Damage to the lungs by pneumotoxicants may lead to massive inflammatory response and consolidation in the alveolar areas, alveolar septa thickening, severe Clara cell hyperplasia or hypertrophy and thickening of the bronchiolar epithelial lining among others (Krijgsheld *et al.*, 1983; Okine *et al.*, 1986, 2005). This may lead to fibrosis as a result of collagen deposition and the lung becoming hypertrophied or oedematous. CE treatment of the animals did not show such marked

changes in the alveolar and bronchiolar areas as seen with known pneumotoxicants, suggesting that the lung was not adversely affected by CE.

The bone marrow is the source of the biosynthesis and release of blood components such as RBCs, WBCs, platelets and others into the blood. Reduction in blood cells may be due to damage or suppression of the bone marrow or direct damage to blood cells. Some chemicals including drugs are known to suppress the bone marrow leading to the impairment of erythropoiesis (Lewis *et al.*, 1997). That CE did not affect any of the haematological indices suggests that it did not suppress or damage the bone marrow or directly affected the blood cells. The lack of effect of CE on blood clotting time suggests that it does not affect vitamin K levels or inhibit the synthesis of blood clotting proteins. The latter is supported by the fact that serum albumin levels were not affected by CE treatment, suggesting that hepatic protein biosynthetic activity was not impaired.

One of the major problems in co-joint administration of drugs is the issue of drug interactions. Herb-drug interactions are known to be caused by phytochemicals which are capable of altering CYP activity (Venkataramanan *et al.*, 2006). For example, hyperforin a chemical constituent with antidepressant properties from the plant *Hypericum perforatum* L., has a strong affinity for Steroid Xenobiotic Receptor (Nathan, 1999). Its binding to the receptor promotes the expression of CYP3A4 gene, thus inducing the enzyme in the liver and intestines resulting in enhanced reduction in the levels of other compounds, whose clearance is mediated by CYP3A4 (Moore *et al.*, 2000; Barone *et al.*, 2001). Pre-treatment of animals with CE did not affect the metabolism and pharmacological effect of pentobarbital expressed as pentobarbital-induced sleeping time. This indicates that CE does not modulate CYP isozymes responsible for the metabolism of pentobarbital. However, the ability of CE to modulate other CYP isozymes responsible for the metabolism of other compounds cannot be overruled.

The most significant finding of this study is the fact that CE significantly inhibited the weight gain of the CE-treated animals. This observation cannot be easily explained since we did not observe any differences in the eating and drinking patterns between CE-treated and control animals. Indeed, the food and drink intakes were similar. However, we observed that the CE-treated animals were leaner although the length of their hind legs and femur were similar to the control (results not shown). It is possible that CE may affect the metabolism and deposition of fat in the animals, thus making them leaner.

It may be concluded that CE does not cause any organ specific toxicity, but its ability to reduce weight gain of animals makes it a candidate plant material for weight loss in obese persons and warrants further studies.

#### ACKNOWLEDGMENTS

The authors will like to express their sincerest gratitude to all the laboratory staff of the Animal Unit of CSRPM, Mampong, Akwapim, Ghana and to Mr. Alex Dodoo, a technical staff at the Electron Microscopy Unit, Noguchi Memorial Institute for Medical Research, University of Ghana, Legon, Ghana.

#### REFERENCES

- Baker, J. and R.E. Silverstone, 1985. Introduction to Medical Laboratory Technology. 6th Edn., Butterworth and Co. Ltd., London, ISBN-10: 0750621907, pp: 172-221.
- Barone, G.W., B.J. Gurley, B.L. Ketel and S.R. Abul-Ezz, 2001. Herbal dietary supplements: a source for drug interactions in transplant recipients. *Transplantation*, 71: 239-241.
- Gaw, A., M. Murphy, R. Cowan, D. O'Reilly, M. Stewart and J. Shepherd, 1998. *Clinical Biochemistry: An Illustrated Colour Text*. Churchill Livingstone, Edinburgh, UK.
- Hedberg, I., O. Hedberg, P.J. Madati, K.E. Mshigeni, E.N. Mshiu and G. Sumuelson, 1982. Inventory of plants used in traditional medicine in Tanzania. 1. Plants of the families Acanthaceae-Cucurbitaceae. *J. Ethnopharmacol.*, 6: 29-60.
- Hutchinson, J., 1967. *The Genera of Flowering Plants (Angiospermae) Dicotyledons*. Vol. 2, Clarendon Press, London, pp: 659.
- Krijgsheld, K.R., M.C. Lowe, E.D. Mimnaugh, M.A. Trush, E. Ginsburg and T.E. Gram, 1983. Lung-selective impairment of cytochrome p450-dependent mono-oxygenases and cellular injury by 1,1-dichloroethylene in mice. *Biochem. Biophys. Res. Commun.*, 110: 675-681.
- Lewis, L.D., A. Benin, C.L. Szumlanski, D.M. Otterness, L. Lennard, R.M. Weinshiloum and D.W. Nierenberg, 1997. Olsalazine and 6-mercaptopurine-related bone marrow suppression: A possible drug-drug interaction. *Clin. Pharmacol. Therapeut.*, 62: 464-475.



- Mitchell, J.C. and W.P. Jordan, 1974. Allergic contact dermatitis from the radish, *Raphanus sativus*. Br. J. Dermatol., 91: 183-189.
- Moore, L.B., B. Goodwin, S.A. Jones, G.B. Wisely and C.J. Serabjit-Singh *et al.*, 2000. St. John's wort induces hepatic drug metabolism through activation of the pregnane X receptor. Proc. Natl. Acad. Sci. (USA), 97: 7500-7502.
- Nathan, P.J., 1999. The experimental and clinical pharmacology of St. John's wort (*Hypericum perforatum* L.). Mol. Psychiatry, 4: 333-338.
- Nyarko, A.K., N.A. Ankrah, M. Ofosuhene and A.A. Sittie, 1999. Acute and subchronic evaluation of *Indigofera arrecta*: Absence of both toxicity and modulation of selected cytochrome P450 isoenzymes in ddy mice. Phytotherap. Res., 1: 666-668.
- Okine, L.K., M.C. Lowe, E.G. Mimnaugh, J.M. Gooche and T.E. Gram, 1986. Protection by methylprednisolone against butylated hydroxytoluene-induced pulmonary damage and impairment of microsomal monooxygenase activities in the mouse: Lack of effect on fibrosis. Exp. Lung Res., 10: 1-22.
- Okine, L.K.N., G.E. Armah, B. Awumbila, O.N.K. Martey and M. Ofosuhene, 2005. Acute and sub-chronic toxicity studies of ADD-203, a fermented ground seed extract of *Cassia occidentalis*, in male Sprague-Dawley rats. J. Ghana Sci. Assoc., 6: 30-38.
- Richter, G., 1980. Allergic contact dermatitis from methyl isothiocyanate in soil disinfectants. Contact Dermat., 6: 183-186.
- Venkataramanan, R., B. Komoroski and S. Stom, 2006. *In vitro* and *in vivo* assessment of herb drug interactions. Life Sci., 78: 2105-2115.